Pediatrics and Neonatology (2016) 57, 155—157

Available online at www.sciencedirect.com

ScienceDirect

journal homepage: http://www.pediatr-neonatol.com

BRIEF COMMUNICATION

Identification and Characterization of Mutations in the *CLCN7* Gene in a Taiwanese Patient with Infantile Malignant Osteopetrosis

Wei-De Lin [a,b], Chung-Hsing Wang [c,d], Kang-His Wu [e,f], I-Ching Chou [g,h], Fuu-Jen Tsai [a,c,f,i,j,*]

[a] *Department of Medical Research, China Medical University Hospital, Taichung, Taiwan*
[b] *School of Post Baccalaureate Chinese Medicine, China Medical University, Taichung, Taiwan*
[c] *Department of Genetics and Metabolism, Children's Hospital of China Medical University, Taichung, Taiwan*
[d] *School of Medicine, China Medical University, Taichung, Taiwan*
[e] *Department of Hematology-Oncology, Children's Hospital of China Medical University, Taichung, Taiwan*
[f] *School of Chinese Medicine, China Medical University, Taichung, Taiwan*
[g] *Department of Neurology, Children's Hospital of China Medical University, Taichung, Taiwan*
[h] *Graduate Institute of Integrated Medicine, China Medical University, Taichung, Taiwan*
[i] *Department of Medical Genetics, China Medical University Hospital, Taichung, Taiwan*
[j] *Department of Health and Nutrition Biotechnology, Asia University, Taichung, Taiwan*

Received Nov 19, 2014; received in revised form Apr 15, 2015; accepted Jul 15, 2015
Available online 13 August 2015

1. Introduction

Osteopetrosis is a rare bone disease characterized by an abnormal increase in bone density and a decrease in bone mechanical strength, and comprises a heterogeneous group of disorders.[1] Autosomal recessive osteopetrosis (ARO) is the most severe form of osteopetrosis, with the most severe symptom being the lack of bone marrow. An abnormal inward expansion of bone cortex interferes with normal medullary hematopoiesis and causes life-threatening pancytopenia and infection.[1]

Several gene mutations are associated with malignant infantile ARO.[2] Because osteopetrosis-associated transmembrane protein-1 (*OSTM1*), T-cell, immune regulator 1, ATPase, H+ transporting, lysosomal V0 subunit A3 (*TCIRG1*), and chloride channel-7 protein (*CLCN7*) mutations account for at least 60% of malignant infantile ARO cases, we selected these genes as the targets of our investigation.[3] Here we report a unique *CLCN7* gene mutation in a Taiwanese patient with malignant infantile ARO.

* Corresponding author. Department of Medical Genetics, China Medical University Hospital, Number 2, Yude Road, 404, Taichung, Taiwan.
E-mail address: d0704@mail.cmuh.org.tw (F.-J. Tsai).

http://dx.doi.org/10.1016/j.pedneo.2015.04.013
1875-9572/Copyright © 2016, Taiwan Pediatric Association. Published by Elsevier Taiwan LLC. All rights reserved.

2. Methods

The patient in this study was a boy, aged 2 years and 9 months. He was the second child born to non-consanguineous, healthy Taiwanese parents, and had two healthy sisters. At 2-months old, his parents noticed poor feeding habits and frequent, irritable crying, however, his general practitioners did not identify any health problems. At 3-months old, he was taken to a local hospital because of his pale appearance and noticeable visceromegaly and diagnosed with thrombocytopenia, borderline anemia, and hepatosplenomegaly, involving the following blood cell counts: white blood cell count, 9200/mL; neutrophil/lymphocyte, 42%/51%; hemoglobin (Hb), 9.2 gm/dL; and platelets, 13,100/mL. A follow-up visit at 5-months old revealed a "failure to thrive" and a developmental delay, which included a head lag while pulling to sit, poor head control, and poor coordination when sucking, swallowing, and breathing. At 7-months of age, a brain computed tomography scan was performed on the patient because of repeated projectile vomiting episodes. The images showed enlargement of brain ventricles, a bulging anterior fontanelle, and diffuse brain atrophy that required a subsequent ventriculoperitoneal shunt to relieve increased intracranial pressure. He was referred to China Medical University Hospital at 2-years-7-months of age because of a continuously worsening pale appearance and an exaggerated abnormal blood profile. At that time, blood work showed life-threatening anemia (Hb, 3.2 gm/dL; mean corpuscular volume, 94.2 fL; reticulocyte count, 15.56%) and the peripheral blood smear test showed leukoerythroblastosis. Aspiration of patient bone marrow was attempted, however, it failed because the patient's bone was too "hard" to allow access to the bone marrow cavity. A skeletal radiographic survey revealed a typical "bone within bone" image and a fractured left humerus (Figure 1). Combined with the other clinical data, ARO was the final diagnosis.

Informed consent was obtained from the parents of the patient to perform a series of genetic analyses. The detailed methods are described in Supplementary Material.

3. Results and discussion

The early onset of patient clinical manifestations and the mode of inheritance were highly compatible with malignant infantile ARO. Linkage analysis was performed to elucidate the mutated gene (*OSTM1*, *TCIRG1*, and *CLCN7*) present in our patient. The short tandem repeat markers in neighboring *OSTM1* and *TCIRG1* did not show segregation with the disease (Figure S1A and S1B) and were, therefore, excluded. As shown in Figure S1C, consideration of D16S423 and D16S407, which were the nearest markers to the *CLCN7* gene, showed that the haplotypes differed between siblings. These markers presented segregation with the disease, revealing *CLCN7* as the pathogenic gene in our patient.

The *CLCN7* gene from the patient was sequenced and two mutations identified (Figure S2). The first mutation was a G-to-A transition at nucleotide position 857 in exon 10 (c.857G>A, p.Arg286Gln) and was inherited from his

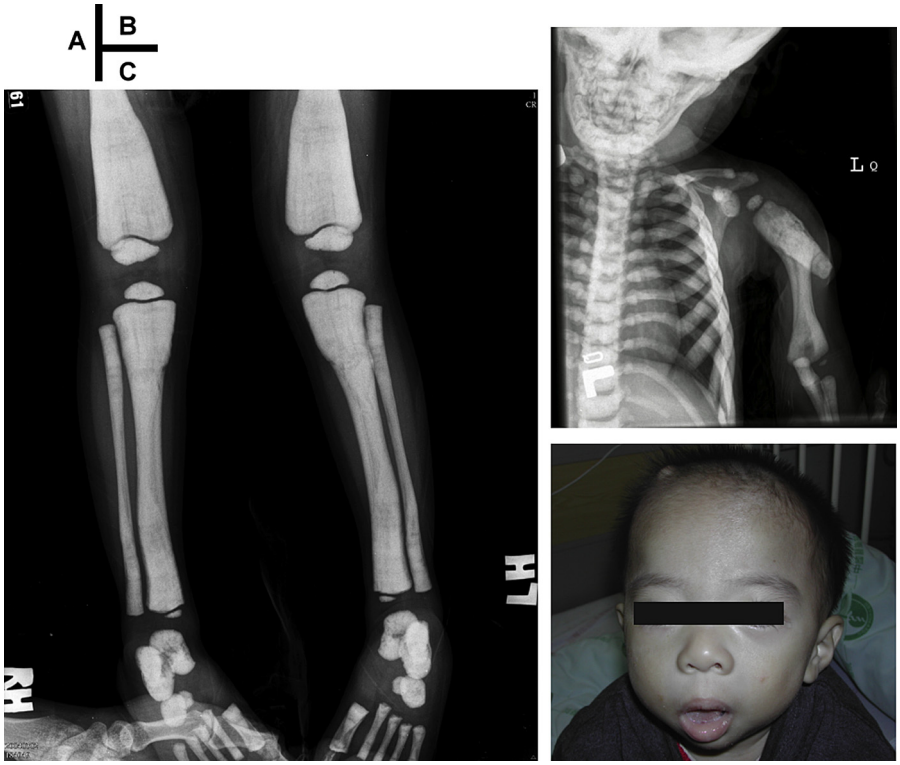

Figure 1 Images of the patient at 2-years-9-months of age. (A) Loss of the bone marrow cavity in the long bones as shown in plain film. (B) Radiographic evidence of a left humerus fracture. (C) Asymmetrical facial expression owing to right facial nerve palsy and a bulging mass over the right parietal area of the scalp disclosing the insertion site of the ventriculoperitoneal shunt.

father. This missense mutation has been previously reported.[4] The other mutation, found in exon 14, was a one-base deletion (c.1168delG) resulting in a translational frameshift from codon 390 and early termination at codon 395 (p.Ala390LeufsTer6). This mutation was inherited from his mother. The elder sister of the patient was also a carrier of the c.1168delG mutation; a one-base deletion mutation that has not yet been reported. This result also corresponded to the linkage analysis. The patient and his elder sister had the same haplotype inherited from their mother, which was the allele carrying the mutation. Neither mutation was detected in 100 healthy volunteers enrolled in the control group. Software packages used for the *in silico* analysis predicted the pathogenicity of both *CLCN7* mutations as follows: PolyPhen2 (S24; likely damaging), Mutation Taster (S23; disease causing), and SIFT (S25; damaging). Two additional single nucleotide polymorphisms, c.1170A>T (p.Ala390Ala) and IVS13-42insC, were found, with both sites linked to the c.1170T polymorphism.

Previously, the p.Arg286Gln mutation was reported in a mild autosomal dominant osteopetrosis (ADO) patient,[4] and a p.Arg286Trp mutation was found in a familial benign ADO case.[5] Here, we determined that although the father of the patient carried one p.Arg286Gln mutation, he remained asymptomatic. The amino acid sequence alignment of seven human CLC chloride channels revealed that Arg286 is not a highly conserved residue.[5] We suspect that CLCN7 with an Arg286 mutation would likely retain some of its original function and that the phenotype associated with a single Arg286 mutation would cause mild or no symptoms associated with ADO. However, if another allele carried a more serious mutation, such as a truncation mutation, the partial function associated with an Arg286-mutated protein would possibly be insufficient to meet physiological requirements and would, therefore, present severe problems. It is likely that the Arg286 mutation would display different influences on ADO and ARO.

There is currently no effective treatment for ARO, especially for malignant infantile ARO. Many types of treatment focus on supportive and symptomatic management of complications.[1] Bone-marrow transplantation (BMT) is an important treatment method that should be considered, but outcomes vary.[6] Before our patient could accept BMT, interferon gamma 1b (INFγ1b) was administered to improve his immune function. INFγ1b was reported to enhance bone resorption and increase bone marrow space.[7] Unfortunately, our patient expired at 4-years of age due to sepsis and before any advanced treatment became available.

4. Conclusion

This study extends the spectrum of *CLCN7* mutations and reveals that the combination of a p.Arg286Gln mutant allele and an allele with a deletion mutation is capable of causing a severe form of ARO. Additionally, *CLCN7* gene profiling may be useful in genetic counseling for families affected by ARO/ADO. Finally, several gene mutations are associated with osteopetrosis and linkage analysis could be used to narrow down the number of genes submitted for sequencing analysis. However, next-generation sequencing technology continues to develop quickly and is now available in several institutions. This new technology can be applied to analyze multiple disease-causing genes simultaneously in order to quickly reveal more detailed DNA variation information and making it useful for the diagnosis of diseases caused by multiple genes, such as osteopetrosis.

Conflicts of interest

The authors declare no conflicts of interest.

Acknowledgments

This work was supported in part by grants from the National Science Council, Taiwan (NSC-102-2314-B-039-031), and China Medical University Hospital, Taichung, Taiwan (#DMR103-040).

References

1. Stark Z, Savarirayan R. Osteopetrosis. *Orphanet J Rare Dis* 2009; **4**:5.
2. Sobacchi C, Schulz A, Coxon FP, Villa A, Helfrich MH. Osteopetrosis: genetics, treatment and new insights into osteoclast function. *Nat Rev Endocrinol* 2013;**9**:522–36.
3. Michou L, Brown JP. Genetics of bone diseases: Paget's disease, fibrous dysplasia, osteopetrosis, and osteogenesis imperfecta. *Joint Bone Spine* 2011;**78**:252–8.
4. Frattini A, Pangrazio A, Susani L, Sobacchi C, Mirolo M, Abinun M, et al. Chloride channel ClCN7 mutations are responsible for severe recessive, dominant, and intermediate osteopetrosis. *J Bone Miner Res* 2003;**18**:1740–7.
5. Cleiren E, Bénichou O, Van Hul E, Gram J, Bollerslev J, Singer FR, et al. Albers-Schönberg disease (autosomal dominant osteopetrosis, type II) results from mutations in the *ClCN7* chloride channel gene. *Hum Mol Genet* 2001;**10**:2861–7.
6. Driessen GJ, Gerritsen EJ, Fischer A, Fasth A, Hop WC, Veys P, et al. Long-term outcome of haematopoietic stem cell transplantation in autosomal recessive osteopetrosis: an EBMT report. *Bone Marrow Transplant* 2003;**32**:657–63.
7. Key Jr LL, Rodriguiz RM, Willi SM, Wright NM, Hatcher HC, Eyre DR, et al. Long-term treatment of osteopetrosis with recombinant human interferon gamma. *N Engl J Med* 1995;**332**:1594–9.

Appendix A. Supplementary data

Supplementary data related to this article can be found at http://dx.doi.org/10.1016/j.pedneo.2015.04.013.